

Associations among the anterior maxillary dental arch form, alveolar bone thickness, and the sagittal root position of the maxillary central incisors in relation to immediate implant placement: A cone-beam computed tomography analysis

Suttikiat Somvasoontra¹, Wichit Tharanon², Pravej Serichetaphongse^{1,3}, Atiphan Pimkhaokham^{1,4,*}

¹*Esthetic Restorative and Implant Dentistry Program, Faculty of Dentistry, Chulalongkorn University, Bangkok, Thailand*

²*Dental Innovation Foundation under Royal Patronage, Bangkok, Thailand*

³*Department of Prosthodontics, Faculty of Dentistry, Chulalongkorn University, Bangkok, Thailand*

⁴*Department of Oral and Maxillofacial Surgery, Faculty of Dentistry, Chulalongkorn University, Bangkok, Thailand*

ABSTRACT

Purpose: This study evaluated the associations of the dental arch form, age-sex groups, and sagittal root position (SRP) with alveolar bone thickness of the maxillary central incisors using cone-beam computed tomography (CBCT) images.

Materials and Methods: CBCT images of 280 patients were categorized based on the dental arch form and age-sex groups. From these patients, 560 sagittal CBCT images of the maxillary central incisors were examined to measure the labial and palatal bone thickness at the apex level and the palatal bone at the mid-root level, according to the SRP classification. The chi-square test, Kruskal-Wallis test, and multiple linear regression were used for statistical analyses.

Results: Significant differences were found in alveolar bone thickness depending on the arch form and SRP at the apex level. The square dental arch form and class I SRP showed the highest bone thickness at both levels of the palatal aspect. The taper dental arch form and class II SRP presented the highest bone thickness at the apex level of the labial aspect. No association was found between the dental arch form and SRP. Elderly women showed a significant association with thinner alveolar bone. Age-sex group, the dental arch form, and SRP had significant associations with alveolar bone thickness at the apex level.

Conclusion: The patient's age-sex group, dental arch form, and SRP were associated with alveolar bone thickness around the maxillary central incisors with varying magnitudes. Therefore, clinicians should take these factors into account when planning immediate implant placement. (*Imaging Sci Dent* 2022; 52: 197-207)

KEY WORDS: Dental Arch; Incisor; Dental Implants; Cone-Beam Computed Tomography

Introduction

Dental implants are the most common treatment option for tooth replacement and enhance oral health-related quality of life, especially when placed in the single anterior maxillary area and when the immediate implant placement protocol is used.¹ Implant rehabilitation in the esthetic area has been a clinical challenge for clinicians in

terms of both functional and esthetic outcomes.

Numerous studies have shown that many factors affect treatment outcomes in this area, including the timing of implant placement, the correct 3-dimensional (3D) position of the fixture, primary stability of the dental implant, and the quantity of available bone.²⁻⁵ The fifth International Team for Implantology consensus recommended a sufficient volume of bone apical and palatal of the extraction site to allow implant insertion in a correct 3D position with sufficient primary stability.³ Grunder et al.⁴ suggested that the labial bone thickness should be at least 2 mm to achieve a long-term esthetic outcome. Kan et al.⁵ classified the sagittal root position (SRP) to provide information on the

Received September 28, 2021; Revised December 13, 2021; Accepted December 29, 2021
Published online March 15, 2022

*Correspondence to : Prof. Atiphan Pimkhaokham

Department of Oral and Maxillofacial Surgery, Faculty of Dentistry, Chulalongkorn University, 34 Henri-Dunant Road, Wangmai, Pathumwan, Bangkok 10330 Thailand
(Tel) 66-2-218-8581, E-mail) atiphan.p@chula.ac.th

Copyright © 2022 by Korean Academy of Oral and Maxillofacial Radiology

This is an Open Access article distributed under the terms of the Creative Commons Attribution Non-Commercial License (<http://creativecommons.org/licenses/by-nc/3.0>) which permits unrestricted non-commercial use, distribution, and reproduction in any medium, provided the original work is properly cited.

Imaging Science in Dentistry · pISSN 2233-7822 eISSN 2233-7830

relationship of the root position with alveolar bone housing by using cone-beam computed tomography (CBCT) in order to assist in proper implant treatment planning. They reported that 86.5% of maxillary central incisor cases were favorable for immediate implant placement.

CBCT is a non-invasive and high-resolution imaging technique widely used in various dental fields, especially for planning implant surgery. CBCT is used to identify vital structures and to evaluate the implant site morphology, quality, and quantity of bone. Several previous studies measured the alveolar bone thickness using CBCT to collect data on bone quantity related to immediate implant placement.^{6,7}

Generally, most patients prefer immediate implant placement because it is less traumatic and involves fewer surgical procedures. Less invasive surgery could reduce the risk from surgical procedures and systemic conditions in all age groups, especially elders.⁸ Elderly persons are considered those aged 65 years or over.⁹ The elderly population is trending upward globally. Some research has suggested chronological age as a risk factor for implant failure due to the nature of systemic diseases and changes in local bone quality and quantity from hormonal factors, as exemplified by osteoporosis.¹⁰ Aging was identified as a factor contributing to reduced thickness of the buccal bone wall of anterior maxillary teeth.¹¹ Sex was also reported to have a negative linear correlation with palatal bone thickness and an association with significantly thinner bone walls in postmenopausal women.^{6,12} Therefore, changes in anterior maxillary alveolar bone thickness would be associated with differences in age and sex.

In implant dentistry, the arch form of the maxilla influences the prosthetic treatment plan, such as stress distribution around the dental implant, the number of implants, and the implant position.^{13,14} In addition, several studies have used CBCT to investigate the relationship between bone quantity and various types of arch forms (e.g., alveolar or dental arch form).^{15,16} Findings from databases of bone quantity from CBCT image files related to the arch form may help predict the quantity of alveolar bone.

Practically, since the cost of CBCT machines remains high, not every dental clinic or hospital can provide CBCT machines for clinicians. Misch¹⁷ presented practical measurement methods to classify the dental arch form by measuring the distance of the anterior cantilever in the premaxillary area from the dental model or intraoral measurement. The premaxillary anterior arch length showed no significant differences according to the class of malocclusion or sex.^{18,19} The shape of the premaxillary arch is maintained

even after tooth extraction. Previous studies have also reported that the accuracy and reliability of tooth dimensions and arch measurements using CBCT are clinically acceptable.^{20,21} Therefore, this study used CBCT images in order to categorize the dental arch form.

Taken together, an understanding of alveolar bone thickness, dental arch form, and SRP could assist the proper planning of implant treatment. Therefore, the objective of this study was to evaluate the associations of the dental arch form, age-sex groups, and SRP with alveolar bone thickness in the maxillary central incisors using CBCT images.

Materials and Methods

Data collection

This retrospective study was conducted with the approval of the Ethics Committee of the Faculty of Dentistry, Chulalongkorn University, Bangkok, Thailand (HREC-DCU-2020-023) and registered with the Thai Clinical Trials Registry (TCTR) with the identification number TCTR20210809005. All data records and Digital Imaging and Communications in Medicine (DICOM) files were retrieved from the computer database of Advanced Medical Devices Technology and Medical Robotics, Pathumthani, Thailand. The data records included patients who were at least 20 years old at the time of the CBCT scan (with data initially recorded between January 2018 to June 2020), with no history of apical surgery, trauma, or orthodontic therapy.

In the CBCT data selection, the inclusion criteria were as follows: 1) all anterior maxillary teeth were fully formed without crowding or spacing; 2) all anterior teeth were not restored with root canal filling materials, dental posts, crowns, or dental implants; and 3) there was no radiographic evidence of restoration, periapical pathology, root resorption, and significant bone loss.

All CBCT images were obtained using a CBCT machine (Planmeca Promax[®] 3D Max, Planmeca, Helsinki, Finland) with 0.40-mm voxel size. The CBCT images were then categorized by sex (men and women) and age group (20-64 years for adults and ≥ 65 years for elders). Age-sex groups were classified as adult men, adult women, elderly men, and elderly women. A single operator recorded all data measurements in this study to ensure uniformity.

Classification and measurement of the dental arch form

The dental arch form was classified based on linear

measurements of the anterior cantilever in the premaxilla area according to Misch's classification.¹⁷ Briefly, the anterior cantilever was described as the distance between 2 imaginary horizontal lines, as detailed in Figure 1. The first imaginary line connected the tip of the upper right canine to the other side, while the second imaginary line was parallel to the first line and passed through the most facial surface of the central incisor. Then, a third imaginary line that was connected and perpendicular with both imaginary horizontal lines at the midline was measured. The distance between 2 lines was referred to as the anterior cantilever. This anterior cantilever represented the dental arch form, which was categorized into 3 groups: square (anterior cantilever < 8 mm), ovoid (anterior cantilever 8-12 mm), and taper (anterior cantilever > 12 mm). However, these measurements were performed clinically.

In this study, due to the accuracy and reliability of CBCT, the measurements were performed using CBCT images with a 3D surface rendering view in CBCT viewing software (Planmeca Romexis Viewer ver. 5.2.0.R, Planmeca, Helsinki, Finland). First, the axes of each CBCT image were reoriented according to Bulyalert and Pimkhaokham's study,¹⁵ with minor modifications. Briefly, the axial plane

was set parallel to the occlusal plane. The sagittal plane was set parallel to the median palatine suture. The coronal plane was created perpendicular to both the axial and sagittal planes. Then, the canine's cusp tip levels, which represented the actual canine cusp tip in the patient's mouth, were identified in the axial plane. The reference points on both canine cusp tips were marked and used as the first imaginary line. The second imaginary line, which ran parallel to the first line, passed through the most facial surface of the central incisor in the axial plane. Both reference lines were reassured in the 3D surface rendering view. Finally, the anterior cantilever was measured using the measuring tool (Fig. 2).

Measurements of labial and palatal alveolar bone thickness

Measurements of labial and palatal alveolar bone thickness were made according to the study of Do et al.⁶ with minor modifications. The DICOM files were imported into CBCT viewing software (Kodak Dental Imaging Software 3D Module 2.4, CodeWeavers Inc., Saint Paul, MN, USA). All CBCT images were sliced at the position of each maxillary central incisor. Thus, all sliced images of the maxillary central incisors were used to measure alveolar bone thickness. In the axial plane, the axes of the teeth were set perpendicular to the labial contour of the alveolar bone, passing through the center of the root canal in the coronal plane and parallel to the root axis in the sagittal plane (Fig. 3).

In the sagittal plane, 4 reference planes that ran perpendicular to the long axis of the root were drawn. The cemento-enamel junction (CEJ) plane was drawn at the CEJ level. The "a" plane was drawn at 3 mm apically from the CEJ level. The "b" plane was drawn at the mid-root (middle distance of 3 mm apically from the CEJ to the root apex level). The "c" plane was drawn at the root apex level. Then,

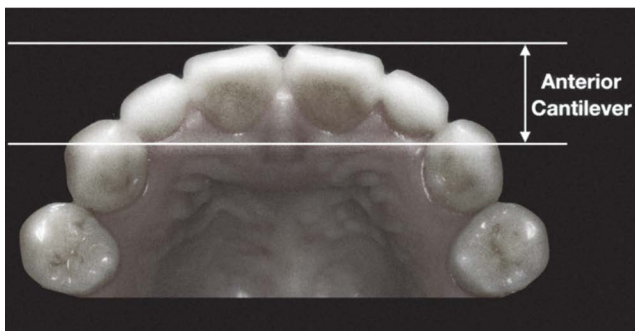


Fig. 1. The anterior cantilever is the distance (mm) between 2 imaginary horizontal lines, as reported by Misch.¹⁷

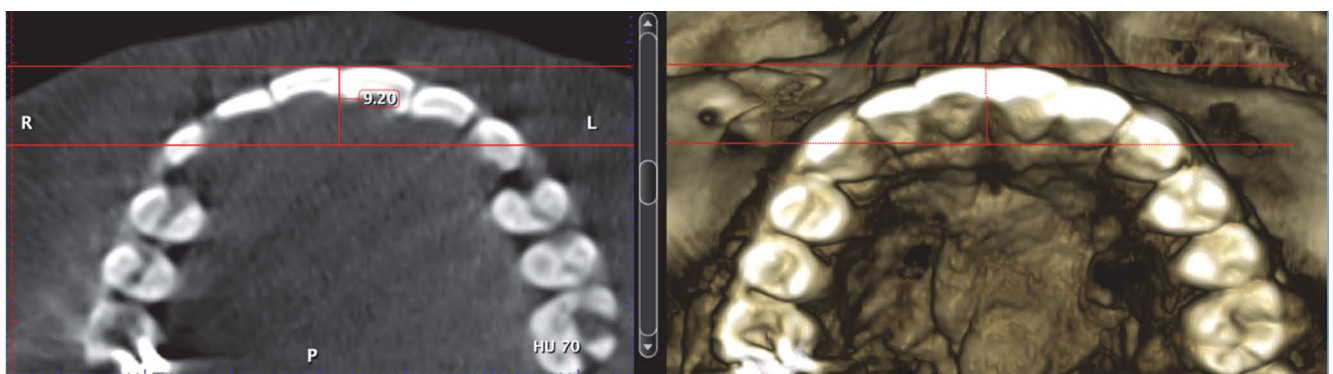


Fig. 2. The dental arch form is classified using the anterior cantilever on axial and 3-dimensional rendering images.

the thicknesses of labial and palatal alveolar bone were measured perpendicular to the long axis of the root as follows: La was defined as the labial alveolar bone thickness at the root apex level, Pa as the palatal alveolar bone thickness at the root apex level, and Pm as the palatal alveolar bone thickness at the mid-root (middle distance of 3 mm apically from the CEJ to the root apex level) (Fig. 4).

SRP classification

The CBCT images of each maxillary central incisor were classified according to the SRP classification presented by Kan et al.,⁵ who categorized the root position

within the bone into 4 classes (classes I, II, III, and IV). In class I, the root is positioned against the labial cortical plate; in class II: the root was centered in the middle of the alveolar housing without engaging either the labial or the palatal cortical plates at the apical third of the root; in class III, the root was positioned against the palatal cortical plate; and in class IV, at least two-thirds of the root engaged both the labial and palatal cortical plates (Fig. 5).

Data analysis

To assure the reliability of the results, the intra-examiner calibration was evaluated using the intraclass correlation coefficient (ICC) for 10 randomly selected subjects to measure all the variables twice. The second measurement was carried out 2 weeks afterward. Then, a 2-way mixed-effect model was used to obtain a 95% confidence interval.

The median and interquartile range of the alveolar bone thickness were calculated according to dental arch forms, age-sex groups, and SRP. The data were analyzed using statistical software (SPSS version 22.0; IBM Corp., Armonk, NY, USA). The chi-square test was used to evaluate the significance of associations between the dental arch form and sex, age group, age-sex groups, and SRP. The normality of the data was determined by the Kolmogorov Smirnov test, while the Kruskal-Wallis test was

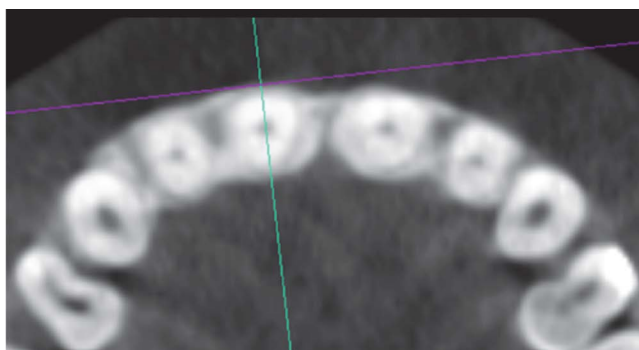


Fig. 3. The labial and palatal bone thickness are measured perpendicular to the alveolar cortical bone from the central slice sagittally.

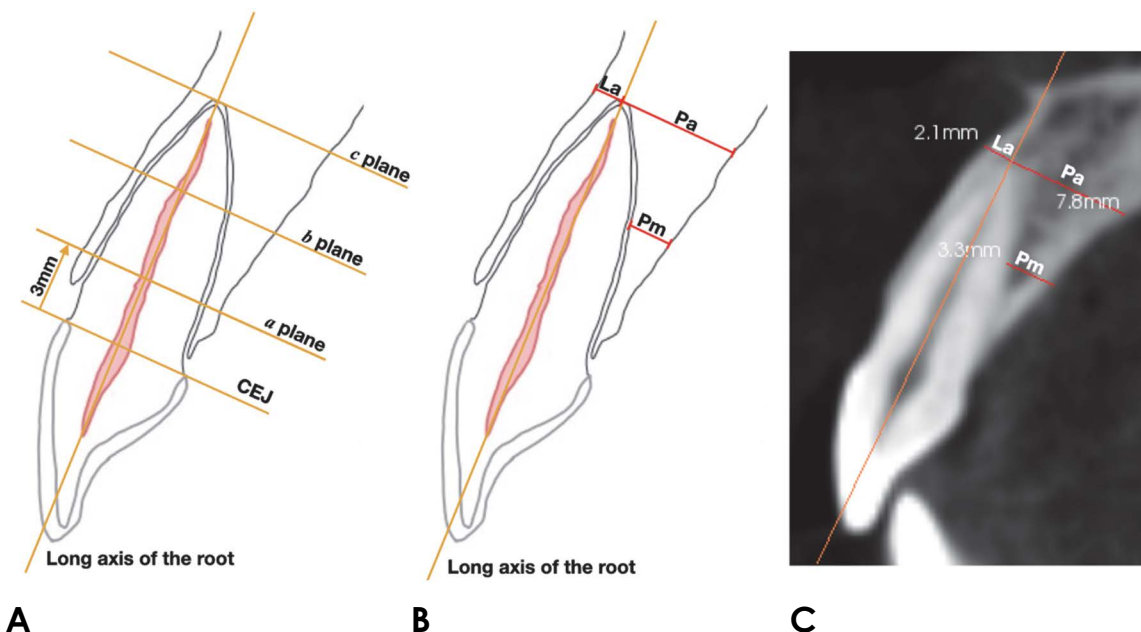


Fig. 4. A. On a sagittal cone-beam computed tomographic image, 4 reference planes are defined perpendicular to the long axis of the root of right central incisor as follows. CEJ: the cemento-enamel junction level of the right central incisor, *a* plane: 3 mm apically from the CEJ level, *b* plane: the level of mid-root (the middle distance of 3 mm apically from the CEJ to the root apex level), *c* plane: the root apex level. B. La: labial alveolar bone thickness at the root apex level, Pa: palatal alveolar bone thickness at the root apex level, Pm: palatal alveolar bone thickness at the mid-root (middle distance of 3 mm apically from the CEJ to the root apex level). C. An example of the measurements.

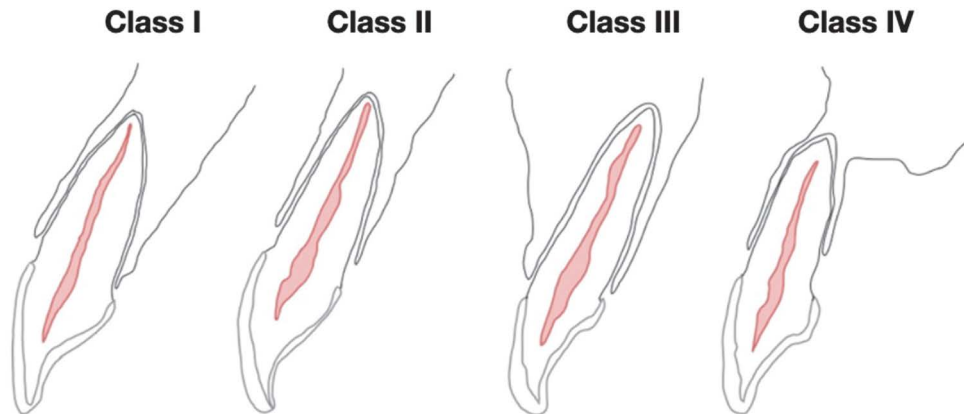


Fig. 5. The sagittal root position classification as reported by Kan et al.⁵

Table 1. Dental arch form distribution (percentage) according to age groups, sex, and age-sex groups

		Square arch (n = 80)	Oval arch (n = 135)	Taper arch (n = 65)
Age (n = 280)	Adult (≥ 20 -64 y)	52 (29.1%)	80 (44.7%)	47 (26.3%)
	Elderly (≥ 65 y)	28 (27.7%)	55 (54.5%)	18 (17.8%)
Sex (n = 280)	Men	36 (29.5%)	54 (44.3%)	32 (26.2%)
	Women	44 (27.8%)	81 (51.3%)	33 (20.9%)
Age-sex (n = 280)	Adult men	22 (30.1%)	28 (38.4%)	23 (31.5%)
	Elderly men	14 (28.6%)	26 (53.1%)	9 (18.4%)
	Adult women	30 (28.3%)	52 (49.1%)	24 (22.6%)
	Elderly women	14 (26.9%)	29 (55.8%)	9 (17.3%)

used to assess the relationships between alveolar bone thickness and dental arch form, age-sex groups, and SRP. Multiple regression was performed to identify predictors of alveolar bone thickness. The oval arch form, class I SRP, and adult men were selected as the reference groups based on their high prevalence in the Thai population. This allowed comparisons between other study groups. $P < 0.05$ was set as the criterion for a statistically significant difference.

Results

In total, 560 CBCT images of the maxillary central incisors from 280 patients (122 men, 158 women) that met this study's criteria were evaluated. Their age ranged from 20 to 81 years (mean, 55 years). The dental arch forms were 80 square arches, 135 oval arches, and 65 taper arches. As shown in Table 1, the distribution of arch forms was not significantly different according to age group, sex, or age-

sex groups. The kappa score, which was used to evaluate the ICC, was 0.996 for the alveolar bone thickness measurements and 0.999 for the anterior cantilever measurements, showing almost perfect agreement.

The median value and interquartile range of alveolar bone thickness of La, Pa, and Pm in each dental arch form are presented in Table 2. La and Pa showed significant differences according to the dental arch form ($P < 0.05$), but Pm did not show a statistically significant difference ($P > 0.05$). The square arch form showed the lowest bone thickness at La and demonstrated a significant difference compared with the taper arch form. In contrast, at Pa, the alveolar bone thickness demonstrated the highest value, with a significant difference from other arch forms. The oval arch form exhibited significantly thinner bone than the square arch form at Pa.

According to age-sex groups, at La, elderly women exhibited the lowest alveolar bone thickness and a significant difference in alveolar bone thickness compared to all other

groups ($P < 0.05$). In addition, adult women showed a significant difference in alveolar bone thickness relative to adult men. At Pa and Pm, adult women and elderly women showed a significant difference in alveolar bone thickness from both adult men and elderly men. In comparison, there was no statistically significant difference between adult

women and elderly women at both Pa and Pm. In addition, there were no statistically significant differences between adult men and elderly men at La, Pa, and Pm (Table 3).

SRP was categorized according to Kan et al.⁵ Most roots of the maxillary central incisors were positioned buccally within the cortical alveolar bone or class I SRP (96.4%). Class III SRP was not found in this study. The distribution and percentage of SRP according to the dental arch form are shown in Table 4. There was no significant relationship between SRP and the dental arch form.

The median value and interquartile range of alveolar bone thickness in each class of SRP are presented in Table 5. La, Pa, and Pm showed significant differences in alveolar bone thickness according to the SRP classification. Class I SRP exhibited the highest alveolar bone thickness at Pa and Pm, while class II SRP exhibited the highest alveolar bone thickness at La. In contrast, class IV SRP showed the lowest alveolar bone thickness at Pa and Pm.

Based on the results from the comparisons in this study,

Table 2. Comparison of the median and interquartile range of the alveolar bone thickness according to the dental arch form (unit: mm)

	Square arch	Oval arch	Taper arch
La	1.45 (1.03-2.10) ^a	1.60 (1.10-2.20)	1.90 (1.30-2.40) ^a
Pa	8.80 (7.23-10.30) ^{a,b}	8.00 (6.68-9.50) ^b	8.05 (6.50-9.43) ^a
Pm	3.80 (3.10-4.90)	3.60 (2.98-4.70)	3.55 (2.68-4.53)

La: labial alveolar bone thickness at the root apex level, Pa: palatal alveolar bone thickness at the root apex level, Pm: palatal alveolar bone thickness at the mid-root (middle distance of 3 mm apically from the CEJ to the root apex level), a, b: horizontally, the same superscript letter indicates significant differences ($P < 0.05$).

Table 3. Comparison of the median and interquartile range of alveolar bone thickness among the age-sex groups (unit: mm)

	Adult men	Elderly men	Adult women	Elderly women
La	2.00 (1.30-2.30) ^{a,b}	1.80 (1.30-2.40) ^c	1.60 (1.10-2.20) ^{a,d}	1.30 (0.90-1.70) ^{b,c,d}
Pa	8.90 (7.50-10.50) ^{a,b}	9.20 (8.00-10.83) ^{c,d}	7.40 (6.30-8.70) ^{a,c}	7.55 (6.43-9.25) ^{b,d}
Pm	4.25 (3.20-5.33) ^{a,b}	4.20 (3.30-5.30) ^{c,d}	3.40 (2.82-4.20) ^{a,c}	3.30 (2.70-4.20) ^{b,d}

La: labial alveolar bone thickness at the root apex level, Pa: palatal alveolar bone thickness at the root apex level, Pm: palatal alveolar bone thickness at the mid-root (middle distance of 3 mm apically from the CEJ to the root apex level), a, b, c, d: horizontally, the same superscript letter indicates significant differences ($P < 0.05$).

Table 4. Dental arch form distribution according to sagittal root position

	Square arch	Oval arch	Taper arch	Overall
Class I	156 (97.5%)	258 (95.6%)	126 (96.9%)	540 (96.4%)
Class II	2 (1.3%)	11 (4.1%)	4 (3.1%)	17 (3%)
Class III	—	—	—	—
Class IV	2 (1.3%)	1 (0.4%)	0 (0%)	3 (0.5%)
Total	160	270	130	560

Table 5. Comparison of the median and interquartile range of sagittal root position among the 3 measurement locations (unit: mm)

	Class I	Class II	Class III	Class IV
La	1.60 (1.10-2.18) ^{a,b}	3.50 (3.00-4.35) ^a	—	3.00 (3.00-3.15) ^b
Pa	8.20 (6.90-9.70) ^{a,b}	6.20 (5.35-7.80) ^a	—	3.00 (3.00-3.70) ^b
Pm	3.75 (3.00-4.80) ^{a,b}	2.80 (2.00-3.90) ^a	—	1.00 (0.75-1.00) ^b

La: labial alveolar bone thickness at the root apex level, Pa: palatal alveolar bone thickness at the root apex level, Pm: palatal alveolar bone thickness at the mid-root (middle distance of 3 mm apically from the CEJ to the root apex level), a, b: horizontally, the same superscript letter indicates significant differences ($P < 0.05$).

Table 6. Summary of the multiple linear regression analysis.

	La	Pa	Pm
R ²	0.237*	0.192*	0.136*
Dental arch form			
Square arch form	-0.153*	0.520*	-
Taper arch form	0.174*	-0.260	-
Sagittal root position			
Class II	1.827*	-2.114*	-1.215*
Class IV	1.438*	-5.698*	-3.348*
Age-sex groups			
Elderly men	0.064	0.195	-0.026
Adult women	-0.119	-1.532*	-0.858*
Elderly women	-0.455*	-1.377*	-1.014*
Constant	1.804*	9.195*	4.467*

La: labial alveolar bone thickness at the root apex level, Pa: palatal alveolar bone thickness at the root apex level, Pm: palatal alveolar bone thickness at the mid-root (middle distance of 3 mm apically from the CEJ to the root apex level), * $P < 0.05$. The oval arch form, class I SRP, and adult men were the reference groups.

the following 3 factors were included in the multiple linear regression model: 1) the type of the dental arch form, 2) SRP classification, and 3) age-sex groups. The type of the dental arch form, SRP classifications, and age-sex groups were significantly associated with alveolar bone thickness at La and Pa ($P < 0.05$, Table 6). However, in the univariate model, the dental arch form was not significantly correlated with the alveolar bone thickness at Pm. Therefore, for Pm, only the SRP classification and age-sex group were used in the multivariate model.

Compared to the alveolar bone thickness of the oval arch form, those in the square arch form demonstrated significantly thinner alveolar bone at La ($P < 0.05$), while significantly thicker alveolar bone was found at Pa ($P < 0.05$). The taper arch form demonstrated significantly thicker alveolar bone at La ($P < 0.05$).

When compared with the alveolar bone thickness of class I SRP, class II and class IV SRP demonstrated significantly thinner alveolar bone at Pa ($P < 0.05$ for both) and Pm ($P < 0.05$ for both), while class II and class IV SRP demonstrated significantly thicker alveolar bone at La ($P < 0.05$ for both).

In terms of age-sex groups, compared to the alveolar bone thickness of adult men, adult women exhibited significantly thinner alveolar bone at Pa ($P < 0.05$), and Pm ($P < 0.05$). In addition, elderly women exhibited significantly thinner alveolar bone at La ($P < 0.05$), Pa ($P < 0.05$), and Pm ($P < 0.05$).

According to the R² of all 3 measurement areas, the

correlation between the predictor variable and the alveolar bone thickness was 23.7% at the La area, 19.2% at Pa, and 13.6% at Pm, as shown in Table 6.

Discussion

This study investigated associations among the dental arch form, age-sex groups, and SRP regarding alveolar bone thickness in the maxillary central incisor using CBCT images. Most previous studies have reported categorizations of the arch form at several levels: alveolar bone, basal bone, and tooth.^{13-16,22} Practically, the premaxillary dental arch form can be classified from an intraoral examination or a stone model without using the arch form template or mathematical calculations.¹⁷ Therefore, the arch form could be a practical parameter for real-world clinical usage. To the best of the authors' knowledge, this was the first study that used the classification of the dental arch form in the premaxillary area to characterize the alveolar bone thickness and SRP.

In this study, a CBCT 3D model was used to classify types of dental arch forms. The benefits of CBCT 3D models are reproducibility, cost-effectiveness, and ease of data manipulation. Many reports showed good accuracy and reliability of linear measurements made on CBCT 3D models and clinically acceptable arch length and tooth size measurements.^{20,21} No significant difference was found in accuracy between a CBCT 3D model, digitalized model, or stone model.^{23,24} However, some studies found variations in the dental arch dimension measurement, as the reference point at the canine cusp tip might have a discrepancy from the canine's marginal ridge or anatomical tooth wear at the functional occlusal plane level.²¹ Thus, to represent the actual cusp tip on a CBCT image, the plane of the axial slice to the most obvious point of both canine cusp tips was modified. This study used the ICC to evaluate the reliability of arch form measurement and showed almost perfect agreement. In the present study, dental arch forms were classified as square, oval, and taper. Previous studies demonstrated that the oval arch form was the most prevalent, similar to the results of this study.²⁵ However, other types of dental arch forms (oval, square, or taper) showed the highest frequency in some studies.^{18,22}

In single tooth replacement of the maxillary central incisor, the practitioner needs to replicate the tooth morphology and gingival margin concerning the CEJ of the contralateral tooth. Previous research suggested placing the implant platform 3-4 mm below the gingival margin for the best esthetic results.^{2,26} The present study deter-

mined the reference plane for the measurement at the pre-determined restorative margin level (3 mm from the CEJ) related to the apex level. The availability of apical and palatal bone could represent the alveolar bone thickness at the appropriate implant position for the immediate implant placement approach according to the recommendation of Morton et al.³

Several studies have focused on alveolar bone thickness, including the labial and palatal aspects. Regarding the labial aspect, Spray et al.²⁷ stated that the critical thickness value that reduces the incidence of facial bone loss is around 2 mm. Grunder et al.⁴ also suggested that the facial bone thickness should be at least 2 mm to provide implant stability and achieve long-term esthetic outcomes. In many studies, most cases showed that the labial bone wall of the anterior maxillary teeth was very thin.^{27,28} Similarly, the present study showed a thin (<2 mm) alveolar labial bone wall at the apical level, similar to the study of Lopez-Jarana et al.²⁹ For the palatal aspect, previous studies showed that the palatal bone thickness was high and increased apically,^{7,30} comparable to the results of this study. According to the restorative-driven surgery concept, Wang et al.³¹ suggested that a dental implant should mimic the natural tooth root in the contralateral and parallel to the tooth root axis. In immediate implant treatment planning, Chung et al.³² recommended that the implant should be placed to mimic the original root angulation, but should be located more palatal due to the thicker palatal native bone. The results from this study assisted in planning according to this concept.

In terms of age and sex difference, the alveolar bone thickness in all measurement areas showed statistically significant differences among groups. On the labial aspect at the apex level, elderly women showed statistically significant differences in alveolar bone thickness from other groups and had the thinnest alveolar bone. Adult and elderly men showed no significant difference in this regard, unlike the significant difference in alveolar bone thickness observed in women. Gakonyo et al.¹¹ reported that the labial alveolar bone thickness decreased with age. Zhang et al.¹² reported that the labial bone was significantly thinner in postmenopausal women due to increasing age and systemic conditions.

The results of the present study showed that increasing age alone was not associated with reduced palatal bone thickness. Adult women and elderly women showed significant differences in alveolar bone thickness relative to adult men and elderly men. Similarly, Do et al.⁶ reported that the palatal bone thickness at the apex level of the maxillary in-

cisors differed significantly between the sexes. Soumya et al.⁷ showed that sex had a significant influence on the palatal alveolar bone thickness. These results suggest that clinicians should be aware of the possibility of minimal labial bone thickness, especially in elderly women.

In terms of SRP, the most prevalent root positions in the alveolar bone housing of maxillary central incisors in this study were class I SRP (96.4%), followed by class II and class IV SRP. Class III SRP was not found within the dataset. The present study classified the SRP based on Kan et al.⁵ The predominance of class I SRP is in accordance with previous studies on Thai and Asian populations. The prevalence of the buccal root position of the maxillary central incisor has been reported to be 92.2% to 95.4%,^{33,34} while class III SRP has been reported as the rarest of all classes.^{8,35} Lombardo et al.³⁶ reported that the dental and alveolar arch forms differed in width and depth in different ethnic groups. Therefore, differences in SRP across studies might be due to ethnic differences.

No association was found between the dental arch form and SRP, while the alveolar bone thickness demonstrated associations with the dental arch form and SRP. This result suggests that only the dental arch form could not be used to predict the SRP classification. Then, the relationships of pairs of variables in the collected data were analyzed.

The alveolar bone thickness was dissimilar according to the dental arch form at the apex level (La and Pa), while there were no differences in the palatal bone thickness at the mid-root (Pm) among the dental arch forms. The square dental arch form showed the thickest alveolar bone in the palatal aspect (Pa), while the labial aspect showed the thinnest bone at the apex level (La). The taper arch form showed the thickest bone at the labial aspect (La), but it was less than 2 mm. The oval arch form, which was the most prevalent type, showed the thinnest alveolar bone at the palatal aspect at the apex level (Pa). Considering the arch form classification in this study, lingual-inclined maxillary central incisors showed less anterior cantilever in the square dental arch form, corresponding to a reduced labial bone thickness at the root apex level, following the study of Tian et al.³⁰ However, the square arch form seemed more favorable for implant anchorage related to immediate implant placement locations due to the greater palatal alveolar bone thickness. Kim et al.³⁷ recommended placing the implant parallel to the labial alveolar plate and slightly inclined more toward the labial edge than towards the incisal edge. Therefore, the taper arch form seemed to be suitable for this concept. Howev-

er, care should be taken to prevent exposure of the dental implant to the labial wall in all arch types because all dental arch forms have shown alveolar bone thickness of less than 2 mm at the labial aspect at the apex level.

Class I SRP showed the thickest bone in the palatal aspect at both the mid-root and palatal levels, but showed the lowest bone thickness at the labial aspect. Class II SRP showed the thickest bone thickness at La (more than 2 mm). Class IV SRP showed the thinnest bone in the palatal areas, as was also reported by Khoury et al.²⁸ This information would help clinicians design the final implant position and angulation related to the alveolar bone thickness. Based on this result, most root positions of maxillary central incisors were located buccally and demonstrated a high quantity of alveolar bone at the palatal sites. As several studies reported, in immediate implant placement, the implant should be placed in the palatal position parallel to the palatal plate to achieve implant stability.³⁸ In class I SRP, the immediate implant position would be most favorable for engaging the apical and palatal bone and gaining primary stability, and the present study supported this concept. However, class II and IV SRP would allow the immediate implant position to follow the tooth socket, engaging the apical bone. This would leave more than 2 mm of labial bone at the implant apex.

This study showed correlations among the dental arch form, SRP, age-sex groups, and alveolar bone thickness. The square arch form showed a positive correlation with alveolar bone thickness at the apex level of the palatal aspect, while a negative correlation was shown at the apex level of the labial aspect. The taper arch form showed a positive correlation only at the apex level of the labial aspect. The dental arch form showed no correlation with the alveolar bone thickness at the mid-root area. Class II and class IV SRP showed negative correlations with alveolar bone thickness at the mid-root and apex levels of the palatal aspect. Age-sex groups also showed inverse associations with alveolar bone thickness. All women had negative correlations at both palatal aspects, while elderly women had more negative correlations at the labial apex level than all other groups. This result agrees with a previous study, which showed significantly higher bone volume in men than in women at the apex and mid-root of maxillary central incisors.^{7,8} In contrast, adult men and elderly men had no significant differences in the correlations to bone thickness. Similar to the findings of Linjawi et al.,³⁹ age and sex showed negative relationships to the anterior maxillary alveolar bone thickness at the apex level. Since some studies found no correlation between

older age and alveolar bone thickness, the findings for this combination of older age and female sex might prove significant. Systemic conditions and post-menstrual syndrome might be a contributor to more bone resorption.

A limitation of this study related to its retrospective nature is the use of various settings of the voxel size. A previous study showed that 0.2-mm or 0.4-mm voxels delivered a similarly accurate 3D CBCT model, and larger voxels could reduce radiation exposure.⁴⁰ In fact, some image viewers could not reconstruct and measure linear distances with a larger voxel size. The difference in voxel size might be problematic in measuring distance in some software. This factor was mitigated in the current study by utilizing an image viewer that could interpret CBCT images at 1-mm intervals (slices). Further research could eliminate this factor entirely by specifying the voxel size used.

In summary, significant pairwise correlations were found in this study. The dental arch form was closely associated with alveolar bone thickness. The square arch form had the thickest palatal bone, while the labial bone in all arch types at the root apex level was thin. The dental arch form did not predict the SRP. Age and sex differences also influenced alveolar bone thickness. Adult women showed a negative correlation with alveolar bone thickness at the palatal aspect, while elderly women showed a negative correlation at all sites. Therefore, the operator should consider the dental arch form and age-sex groups with great caution and inform patients, especially elderly women, about their bone condition. Bone volume prediction considering these factors could aid in planning immediate implant placement at the maxillary central incisor site. This would result in better aesthetic outcomes and long-term success.

Acknowledgments

The authors thank Assistant Professor Dr. Soranun Chantrangsung for her excellent recommendations and help regarding statistical analysis.

Conflicts of Interest: None

References

1. Testori T, Weinstein T, Scutellà F, Wang HL, Zucchelli G. Implant placement in the esthetic area: criteria for positioning single and multiple implants. *Periodontol* 2000 2018; 77: 176-96.
2. Buser D, Martin W, Belser UC. Optimizing esthetics for im-

- plant restorations in the anterior maxilla: anatomic and surgical considerations. *Int J Oral Maxillofac Implants* 2004; 19 Suppl: 43-61.
3. Morton D, Chen ST, Martin WC, Levine RA, Buser D. Consensus statements and recommended clinical procedures regarding optimizing esthetic outcomes in implant dentistry. *Int J Oral Maxillofac Implants* 2014; 29 Suppl: 216-20.
 4. Grunder U, Gracis S, Capelli M. Influence of the 3-D bone-to-implant relationship on esthetics. *Int J Periodontics Restorative Dent* 2005; 25: 113-9.
 5. Kan JY, Roe P, Rungcharassaeng K, Patel RD, Waki T, Lozada JL, et al. Classification of sagittal root position in relation to the anterior maxillary osseous housing for immediate implant placement: a cone beam computed tomography study. *Int J Oral Maxillofac Implants* 2011; 26: 873-6.
 6. Do TA, Shen YW, Fuh LJ, Huang HL. Clinical assessment of the palatal alveolar bone thickness and its correlation with the buccolingual angulation of maxillary incisors for immediate implant placement. *Clin Implant Dent Relat Res* 2019; 21: 1080-6.
 7. Soumya P, Chappidi V, Koppolu P, Pathakota K. Evaluation of facial and palatal alveolar bone thickness and sagittal root position of maxillary anterior teeth on cone beam computerized tomograms. *Niger J Clin Pract* 2021; 24: 329-34.
 8. Schimmel M, Müller F, Suter V, Buser D. Implants for elderly patients. *Periodontol* 2000 2017; 73: 228-40.
 9. United Nations, Department of Economic and Social Affairs, Population Division. World population ageing 2019 (ST/ESA/SER.A/444) [Internet]. New York: United Nations; 2020 [cited 2021 Sep 28]. Available from <https://www.un.org/en/development/desa/population/publications/pdf/ageing/WorldPopulationAgeing2019-Report.pdf>.
 10. Moy PK, Medina D, Shetty V, Aghaloo TL. Dental implant failure rates and associated risk factors. *Int J Oral Maxillofac Implants* 2005; 20: 569-77.
 11. Gakonyo J, Mohamedali AJ, Mungure EK. Cone beam computed tomography assessment of the buccal bone thickness in anterior maxillary teeth: relevance to immediate implant placement. *Int J Oral Maxillofac Implants* 2018; 33: 880-7.
 12. Zhang CY, DeBaz C, Bhandal G, Alli F, Buencamino Francisco MC, Thacker HL, et al. Buccal bone thickness in the esthetic zone of postmenopausal women: a CBCT analysis. *Implant Dent* 2016; 25: 478-84.
 13. Bidez MW, Misch CE. Clinical biomechanics in implant dentistry. In: Misch CE. *Dental implant prosthetics*. 2nd ed. St. Louis: Mosby; 2005. p. 95-106.
 14. Zarei M, Jahangirnezhad M, Yousefimanesh H, Robati M, Robati H. A comparative study on the stress distribution around dental implants in three arch form models for replacing six implants using finite element analysis. *J Indian Soc Periodontol* 2018; 22: 127-32.
 15. Bulyalert A, Pimkhaokham A. A novel classification of anterior alveolar arch forms and alveolar bone thickness: a cone-beam computed tomography study. *Imaging Sci Dent* 2018; 48: 191-9.
 16. Ansari T, Mascarenhas R, Husain A. The relationship of various arch forms and cortical bone thickness. *J Dent (Tehran)* 2011; 8: 7-11.
 17. Misch CE. Maxillary arch implant considerations: fixed and overdenture prosthesis. In: Misch CE. *Contemporary implant dentistry*. 3rd ed. St. Louis: Mosby Elsevier; 2008. p. 367-88.
 18. Al Shammout RW, Al Jabrah O, Aburumman K, Alhababba AM, Almanaseer W. The effect of various classes of malocclusions on the maxillary arch forms and dimensions in Jordanian population. *Adv Dent Oral Health* 2016; 2: 17-23.
 19. Al-Zubair NM. Determinant factors of Yemeni maxillary arch dimensions. *Saudi Dent J* 2015; 27: 50-4.
 20. Baumgaertel S, Palomo JM, Palomo L, Hans MG. Reliability and accuracy of cone-beam computed tomography dental measurements. *Am J Orthod Dentofacial Orthop* 2009; 136: 19-28.
 21. Alam MK, Shahid F, Purmal K, Ahmad B, Khamis MF. Bolton tooth size ratio and its relation with arch widths, arch length and arch perimeter: a cone beam computed tomography (CBCT) study. *Acta Odontol Scand* 2014; 72: 1047-53.
 22. Tajik I, Mushtaq N, Khan M. Arch forms among different angle classifications - a study. *Pak Oral Dent J* 2011; 31: 92-5.
 23. Tarazona B, Llamas JM, Cibrian R, Gandia JL, Paredes V. A comparison between dental measurements taken from CBCT models and those taken from a digital method. *Eur J Orthod* 2013; 35: 1-6.
 24. El-Zanaty HM, El-Beialy AR, Abou El-Ezz AM, Attia KH, El-Bialy AR, Mostafa YA. Three-dimensional dental measurements: an alternative to plaster models. *Am J Orthod Dentofacial Orthop* 2010; 137: 259-65.
 25. Shafique A, Saleem T, Chattha MR. Arch form analyses: a comparison of two different methods. *Pak Oral Dent J* 2011; 31: 347-51.
 26. Palacci P, Nowzari H. Soft tissue enhancement around dental implants. *Periodontol* 2000 2008; 47: 113-32.
 27. Spray JR, Black CG, Morris HF, Ochi S. The influence of bone thickness on facial marginal bone response: stage 1 placement through stage 2 uncovering. *Ann Periodontol* 2000; 5: 119-28.
 28. Khoury J, Ghosn N, Mokbel N, Naaman N. Buccal bone thickness overlying maxillary anterior teeth: a clinical and radiographic prospective human study. *Implant Dent* 2016; 25: 525-31.
 29. López-Jarana P, Díaz-Castro CM, Falcão A, Falcão C, Ríos-Santos J, Herrero-Climent M. Thickness of the buccal bone wall and root angulation in the maxilla and mandible: an approach to cone beam computed tomography. *BMC Oral Health* 2018; 18: 194.
 30. Tian YL, Liu F, Sun HJ, Lv P, Cao YM, Yu M, et al. Alveolar bone thickness around maxillary central incisors of different inclination assessed with cone-beam computed tomography. *Korean J Orthod* 2015; 45: 245-52.
 31. Wang HM, Shen JW, Yu MF, Chen XY, Jiang QH, He FM. Analysis of facial bone wall dimensions and sagittal root position in the maxillary esthetic zone: a retrospective study using cone beam computed tomography. *Int J Oral Maxillofac Implants* 2014; 29: 1123-9.
 32. Chung SH, Park YS, Chung SH, Shon WJ. Determination of implant position for immediate implant placement in maxillary central incisors using palatal soft tissue landmarks. *Int J Oral Maxillofac Implants* 2014; 29: 627-33.

33. Benjasupattananan S, Sirikururat P. Relationship between facial alveolar bone thickness and root position of maxillary anterior teeth using cone beam computed tomography. *J Dent Assoc Thai* 2018; 68: 38-47.
34. Xu D, Wang Z, Sun L, Lin Z, Wan L, Li Y, et al. Classification of the root position of the maxillary central incisors and its clinical significance in immediate implant placement. *Implant Dent* 2016; 25: 520-4.
35. Petaibunlue S, Serichetaphongse P, Pimkhaokham A. Influence of the anterior arch shape and root position on root angulation in the maxillary esthetic area. *Imaging Sci Dent* 2019; 49: 123-30.
36. Lombardo L, Coppola P, Siciliani G. Comparison of dental and alveolar arch forms between different ethnic groups. *Int Orthod* 2015; 13: 462-88.
37. Kim JH, Lee JG, Han DH, Kim HJ. Morphometric analysis of the anterior region of the maxillary bone for immediate implant placement using micro-CT. *Clin Anat* 2011; 24: 462-8.
38. Gómez-Polo M, Ortega R, Gómez-Polo C, Martín C, Celemín A, Del Río J. Does length, diameter, or bone quality affect primary and secondary stability in self-tapping dental implants? *J Oral Maxillofac Surg* 2016; 74: 1344-53.
39. Linjawi A. Predictive factors affecting the maxillary alveolar bone thickness: a cone-beam computed tomography study. *Clin Cosmet Investig Dent* 2020; 12: 359-65.
40. Mukhia N, Birur NP, Shubhasini AR, Shubha G, Keerthi G. Dimensional measurement accuracy of 3-dimensional models from cone beam computed tomography using different voxel sizes. *Oral Surg Oral Med Oral Pathol Oral Radiol* 2021; 132: 361-9.